



**PATIENT PRESENTING CLINICAL SIGNS**

**Kiwi Gomez** History: 2-week duration of loss of appetite, vomiting, and diarrhea with recently showing some improvement.

**SPECIES** Physical Examination: N/A.

Canine Urinalysis: N/A.

**BREED** CBC: N/A.

West Highland Terrier Serum Biochemistry: N/A.

Radiographic Findings: N/A.

**SEX**

MN

**AGE**

6 years

**WEIGHT**

19.1 #

**INTERPRETED BY**

Remo Lobetti, BVSc,  
MMedVet (Med), PhD, Dipl.  
ECVIM

**ULTRASONOGRAPHIC EXAMINATION OF THE ABDOMEN**

**Urinary System**

Small urinary bladder with normal thickness and appearance of the wall. Normal anechoic urine with no sediment or uroliths evident.

Normal trigone area, proximal urethra, and iliac blood vessels.

Normal iliac lymph nodes. Ureters not visualized.

Normal renal size, echogenic appearance, cortico-medullary differentiation, pelvis, and capsule.

**Reproductive System**

Small hypoechogenic prostate (1.2 cm).

**IMAGING PERFORMED BY**

Dr Paul Kim

**Adrenal Glands**

Normal shape, echogenic appearance, position, and size. Left 1.01 x 0.3 cm, right 0.67 x 0.37 cm.

**HOSPITAL NAME**

Ridgefield Park Animal  
Hospital

**Spleen**

Normal size and echogenic appearance. Smooth homogenous parenchyma, regular capsule, and normal vasculature. No evidence of inflammatory, neoplastic, infarction, or infiltrative changes noted.

**REFERRING VET**

Dr Paul Kim

**Liver**

Normal size, echogenic appearance, and portal markings. No nodules or masses evident. Small gall bladder containing normal anechoic bile. Thickened and hyperechogenic appearance of the gall bladder wall. Normal bile duct.

**INVOICE**

303162

**Gastrointestinal**

**DATE**

8/3/22

Normal appearance of the stomach, duodenum, small intestine, ileo-cecal junction, and colon with no loss of layering, normal wall thickness and peristaltic activity, and no distension of the lumen. Ingesta within the stomach, chyle within the small intestine.



**PATIENT** *Pancreas*

Kiwi Gomez Normal size (right 0.7 cm, left 0.4 cm) and echogenic appearance. Regular capsule. Normal echogenic appearance of the mesentery and fat surrounding the pancreas.

**SPECIES** *Free Abdomen*

Canine No mesenteric lymphadenomegaly.  
No ascites.

**BREED** Small aortic thrombus (0.5 cm).

West Highland Terrier

**ULTRASONOGRAPHIC FINDINGS**

**SEX** Primary Findings:

- MN
- Thrombus.
  - Ingesta/chyle filled stomach and small intestine.

**AGE** Secondary Findings:

- 6 years
- Previous cholecystitis.

**WEIGHT**

19.1 #

**INTERPRETATION OF THE FINDINGS & FURTHER RECOMMENDATIONS**

**INTERPRETED BY**

Remo Lobetti, BVSc,  
MMedVet (Med), PhD, Dipl.  
ECVIM

The ingesta within the stomach and chyle within the small intestine is most likely from a recent meal, however, with the presenting clinical signs resolving non-specific gastroenteritis, inflammatory bowel disease, dietary hypersensitivity, and parasitic enteritis (helminths, protozoa) needs to be considered.

Further assessment would be fecal analysis, serum proteins, cobalamin assay, coagulation profile, and possibly echocardiography and endoscopy of the upper GI tract with biopsies.

**IMAGING PERFORMED BY**

Dr Paul Kim

Specific therapy would be dependent on an etiological diagnosis. Symptomatic therapy would be novel protein/hypoallergenic diet, cobalamin supplementation, course of fenbendazole and/or metronidazole, and possible clopidogrel

**HOSPITAL NAME**

Ridgefield Park Animal  
Hospital

**REFERRING VET**

Dr Paul Kim

**INVOICE**

303162

**DATE**

8/3/22



**PATIENT IMAGES**

Kiwi Gomez **Aorta**

**SPECIES**

Canine

**BREED**

West Highland Terrier

**SEX**

MN

**AGE**

6 years

**WEIGHT**

19.1 #

**INTERPRETED BY**

Remo Lobetti, BVSc,  
MMedVet (Med), PhD, Dipl.  
ECVIM

**IMAGING PERFORMED BY**

Dr Paul Kim

**HOSPITAL NAME**

Ridgefield Park Animal  
Hospital

**REFERRING VET**

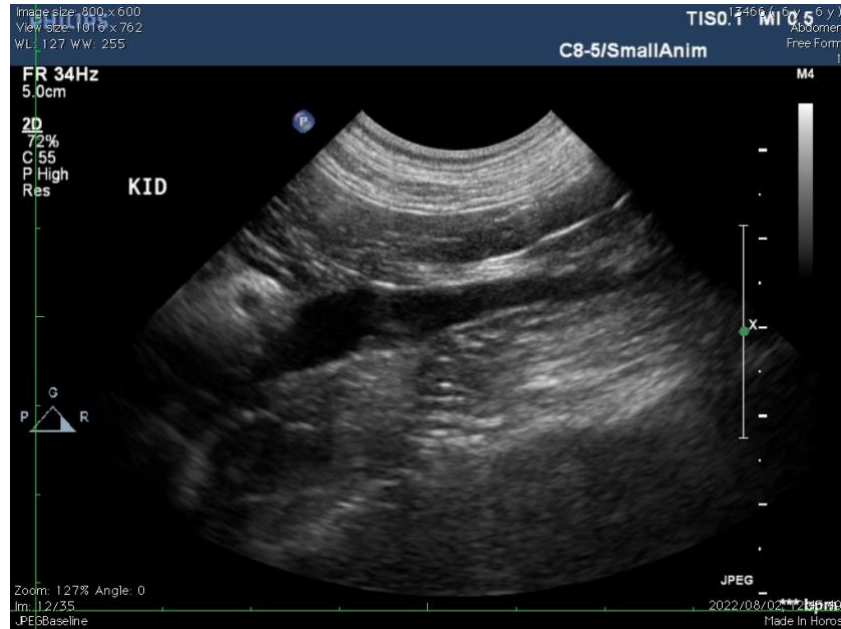
Dr Paul Kim

**INVOICE**

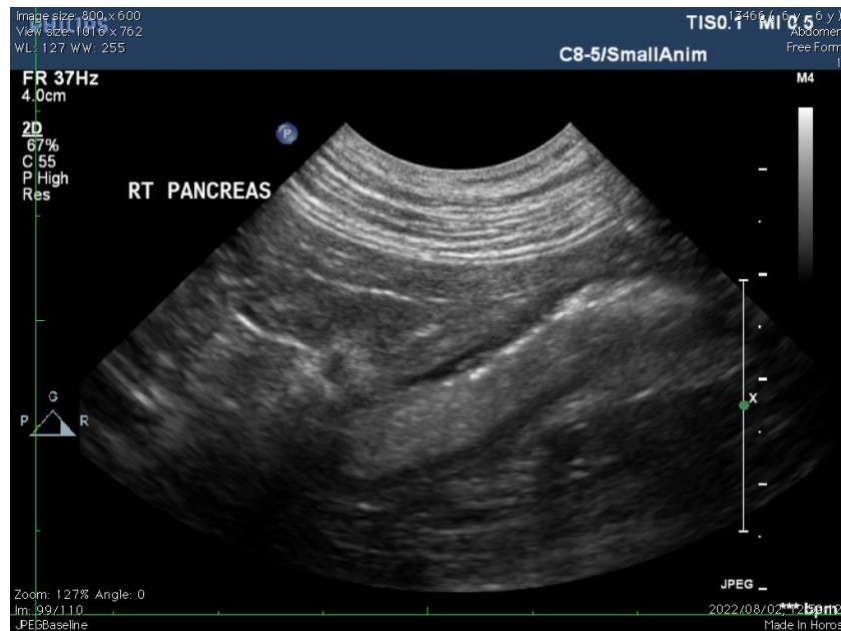
303162

**DATE**

8/3/22



**Small intestine**





**PATIENT** Gall bladder

Kiwi Gomez

**SPECIES**

Canine

**BREED**

West Highland Terrier

**SEX**

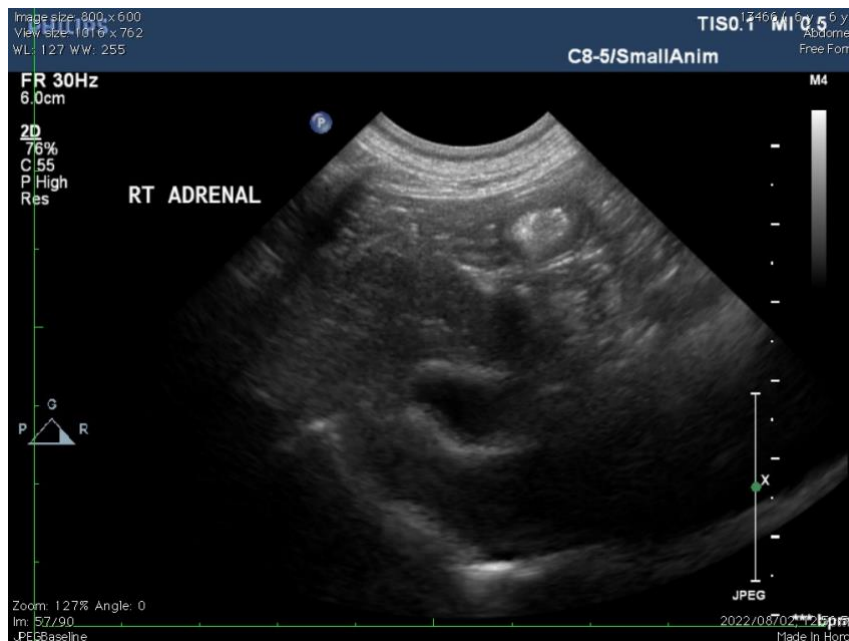
MN

**AGE**

6 years

**WEIGHT**

19.1 #



**INTERPRETED BY**

Remo Lobetti, BVSc, MMedVet (Med), PhD, Dipl. ECVIM

The information and recommendations provided are based on the images presented by the referring veterinarian. No evaluation can be communicated regarding pathology that was not visible in the image/video clips provided.

Thank you for this referral. If the clinical or image interpretation does not parallel your findings or if I can be of any further assistance, please contact me.

**Remo Lobetti, BVSc, MMedVet (Med), PhD, Dipl. ECVIM (Internal Medicine)**  
[rlobetti@mweb.co.za](mailto:rlobetti@mweb.co.za)

**IMAGING PERFORMED BY**

Dr Paul Kim

**HOSPITAL NAME**

Ridgefield Park Animal Hospital

**REFERRING VET**

Dr Paul Kim

**INVOICE**

303162

**DATE**

8/3/22